

Systematic interpretation of chest radiographs in the ICU

Jeff Anderson, MA, RRT
Department of Respiratory Care
Boise State University

Normal CXR report & eye search

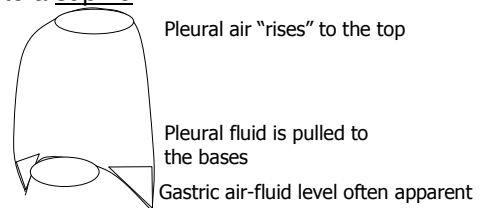
- No significant tracheal displacement or active pleural process
- Normal heart size
- No hilar or mediastinal lesion
- The lungs are clear
- Unremarkable bones and soft tissues
- Identify tubes, lines, & their positions

Before interpreting your film

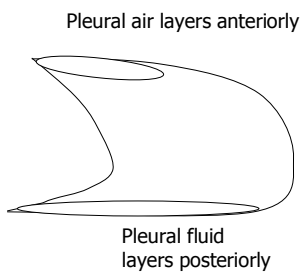
- Ensure that it is the correct date, time, patient
- Identify the patient's position
 - Bed side films will be APs
 - May be upright, semi-upright, supine
- Look for rotation

Upright chest radiographs

- How would an upright film compare to a supine film?



Supine chest radiographs



Normal CXR report

- Normal heart size
 - The heart should be no more than $\frac{1}{2}$ the width of the chest
 - Cardiothoracic ratio